

PATIENT PRESENTING CLINICAL SIGNS

Maggie Papillon
History: Frequent coughing, 2/6 murmur
Medication: Proin, Dasuquin

SPECIES ECHOCARDIOGRAPHIC FINDINGS

Canine Multiple 2D, M-mode, and Doppler video loops and still images are submitted for review.

BREED Left atrial size is normal. The mitral valve leaflets are mildly thickened, and a mild jet of eccentric mitral regurgitation is present. Left ventricular dimensions are normal. Left ventricular systolic function is normal. The aorta and aortic valve are normal. Right atrial and right ventricular dimensions are normal. The tricuspid valve leaflets are mildly thickened, and a mild jet of tricuspid regurgitation is present. The pulmonary artery and pulmonic valve are normal. No heartworms are visualized. No pericardial effusion or cardiac masses are seen.

SEX

FS

AGE

15 years

WEIGHT

43.6#

LA - 39.5 mm
LVIDd - 39.4 mm
LVIDs - 27.2 mm
FS - 31%
RA - 25.7 mm
LVOT - 1.39 m/s
RVOT - 0.88 m/s

ASSESSMENT/RECOMMENDATIONS

Degenerative mitral and tricuspid valve disease

INTERPRETED BY

Keith Blass, DVM,
MS, DACVIM

This examination demonstrates mild regurgitation of blood across Maggie's mitral and tricuspid valves resulting from degenerative valve disease. The hemodynamic effects of each of the regurgitations also appear to be mild, as Maggie does not have secondary dilation of any of her cardiac chambers. As such, Maggie's valvular diseases appear to be well-compensated, and, while a definitive reason for Maggie's cough is not appreciated in her radiograph, it does not appear that her cough is cardiogenic in origin.

IMAGING PERFORMED BY

Rebekah Jakum, CVT
ARDMS/RVT

No therapy is recommended at this stage of Maggie's valvular diseases.

A recheck echocardiogram is recommended in ~6 months to monitor for disease progression.

HOSPITAL NAME

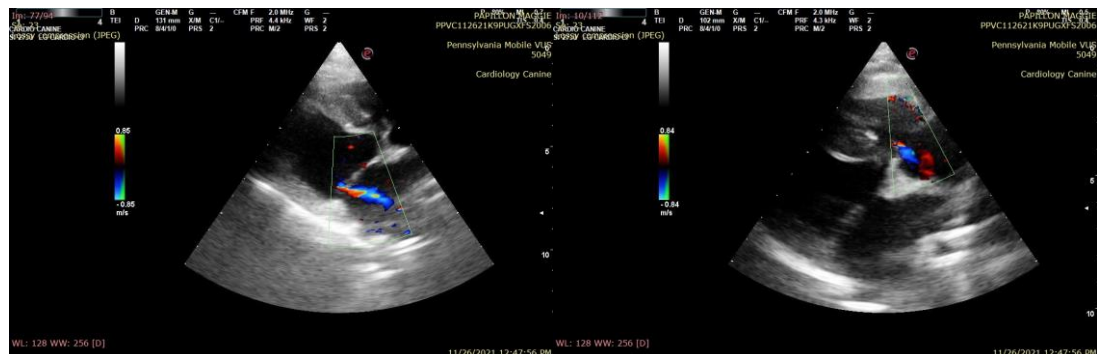Pocono Peak VC

REFERRING VET

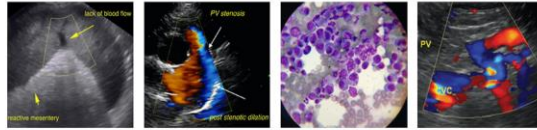
Dr. Carney

DATE

11.27.2021



The information and recommendations provided are based on the images presented by the referring veterinarian. No evaluation can be communicated regarding pathology that was not visible in the



PATIENT image/video clips provided.

Maggie Papillon Thank you for this referral. If the clinical or image interpretation does not parallel your findings or if I can be of any further assistance please contact me.

SPECIES

Canine **Keith Blass, DVM, MS, DACVIM (Cardiology)**

KeithBlass@gmail.com

BREED 631-804-5754

Pug Mix

SEX

FS

AGE

15 years

WEIGHT

43.6#

INTERPRETED BY

Keith Blass, DVM,
MS, DACVIM

**IMAGING
PERFORMED BY**

Rebekah Jakum, CVT
ARDMS/RVT

HOSPITAL NAME

Pocono Peak VC

REFERRING VET

Dr. Carney

DATE

11.27.2021